

## Scalp Reconstruction Using Tissue Expander

YOUSSEF SALEH, M.D.

*The Department Plastic and Reconstructive Surgery, Faculty of Medicine, Assiut University.*

### ABSTRACT

Tissue expansion has enjoyed a wide range of application since the technique was popularized by Radovan in 1978. Tissue expansion is one of the most important armamentaria for aesthetic scalp reconstruction. This study includes 40 patients presenting by various types of alopecia of different etiology. 35 patients underwent single session of expansion, three of them underwent two sessions of expansion and the last two cases underwent three sessions of expansion. The overall complication was 34.75%, there was good and satisfactory coverage in 87% of cases.

### INTRODUCTION

The proper way for scalp reconstruction usually presents a challenge to plastic surgeon due to several factors including inelastic nature of scalp and special hairy nature of scalp skin [1]. Neumann in 1956 followed by Radovan in 1976 recognized the potential of tissue expansion for reconstructive surgery [2]. Subsequently, the use of tissue expansion has been popularized among plastic surgeons and has become the treatment of choice for scalp reconstruction either in children or adults [3].

Scalp expansion has many advantages including no new unduly disfiguring defects, the avoidance of distant flaps, sensation maintenance, good color and texture match, preservation of hair bearing quality and increased vascularity of elevated expanded flaps. However, there are several disadvantages to expansion as frequent visit for inflation, discomfort and period of increased deformity during the time of inflation, also in pediatric population emotional disturbances may accompany the use of tissue expansion [4].

### PATIENTS AND METHODS

During the time period from June 2000 to March 2003, 40 patients were admitted in plastic surgery department and underwent scalp expansion for management of alopecia of different sizes and sites.

Their ages ranged from 5 years to 45 years with a mean age 19.1 years. Twenty-eight of them were females and twelve were males.

The most common etiology for alopecia was burn, followed by trauma and lastly infection. The site of alopecia varied among the scalp, however, the most common one was parietal and temporal area, followed by frontal one and lastly occipital area. The size of alopecic area varied from 4 x 6 cm to 10 x 24 cm.

A detailed pre-surgical sheet for every patient included:

- Personal data in details.
- Type and onset of alopecia.
- Pattern of hair loss.

Family history and general health.

- Medications (systemic drugs or topical application on the scalp).

#### 1- Pre-operative data:

All patients' acquired hair washing by betadine lotion at the night of operation.

Surgical fitness investigations were done (as C.B.C., S. urea and creatinine, B1. Sugar, Prothrombin time and concentration).

A written consent was signed by every patient, describing the details of the procedure and possible complications with pre-operative photography for every patient for medical documentation.

#### 2- Surgical technique:

The choice of expander usually was determined intraoperatively according to the size and shape of the alopecic area.

Under general anesthesia and complete aseptic

condition, an incision was done in the scarred area 1 cm away from the hair-bearing area, the dissection was performed in subgaleal plane. Adequate pocketing and good homeostasis was done and then the expander was inserted and slightly inflated to minimize the dead space. Lastly the skin was closed by direct closure using 3/0 proline.

After a latent period of 10 days, subsequent inflation of the expander was done by injection of saline twice-weekly using butterfly needle, enough saline is placed to achieve tensesness of overlying skin or to produce mild discomfort.

Serial injections are continued until excessive amount of soft tissue has been generated to allow closure of the defect in an anatomic and aesthetic manner.

At the second procedure, the expander is removed, the capsule is incised to facilitate advancement of the flap, then the scarred area was excised and the flap is inset.

Suction drain was left for 72 hours, the skin usually closed directly.

All patients received a broad-spectrum bactericidal antibiotic with frequent washing of the hair 2 days post-operatively using betadine lotion.

Stitches were removed from 7-10 days. Post-operative photography was done in all cases. In this study thirty five cases in which the alopecic area varied from 4 x 6 cm to 5 x 7 cm acquired single session of expansion and the remaining five cases as the following. Three cases with the alopecic area from 6 x 10 cm to 7 x 15 cm underwent two sessions of expansion and two cases with the alopecic area more than 8 x 15 cm up to 10 x 24 cm underwent three sessions of expansion.

The average time for full expansion was 45 days.

*Follow up:* The mean follow up period ranged from 10 months to 32 months with mean follow up period 22 months.

## RESULTS

As regard age, the most common age was mid-age group from 15y-30y (28 patients) (Table 1).

The most common etiology of alopecia was burn (25 cases) (Table 2).

The most common site of alopecia was parietal and temporal area (22 cases) (Table 3).

The most common shape of expander used in scalp reconstruction was rectangular one (23 cases) (Table 4).

*Every patient was evaluated as follows:*

A- Minor complications (21.5%): which did not interrupt the expansion process includes:

- 1- Seroma: developed in three cases (8.25%) in immediate post-operative period, which rapidly respond to repeated aspiration and strong antibiotic and anti-inflammatory, also the patient underwent smooth postoperative course and normal expansion.
- 2- Haematoma: developed in two cases (5%) in immediate post-operative due to obstruction of suction drain, removal of the drain was done, a small tube was inserted through the same slit on bed and repeated aspiration was done, also this did not interrupt the expansion process.
- 3- Wound dehiscence: occurred in three cases (8.25%) in seventh day post-operative, those patients underwent secondary suture in operative theatre with strong broad-spectrum antibiotic, the starting of expansion process was delayed for two weeks till complete healing was achieved.

B- Major complications (13.25%): in which the expansion process was stopped with removal of the expander including:

- 1- Infection: profound infection developed into three cases (8.25%), in third day post-operative, the expander was immediately removed in operative theatre, under cover of broad spectrum antibiotic and anti-inflammatory for one week till complete fading of infection and those patients acquired another operation for expansion after 6 months.
- 2- Expander extrusion: occurred in two cases (5%) during the expansion process, immediate extraction of expander was done in operative theatre, under cover of broad spectrum antibiotic, those patients acquired a secondary procedure after 6 months.

C- Quality of coverage:

- 1- Satisfactory coverage: was achieved in 35 cases (87.5%), either from single session or multiple

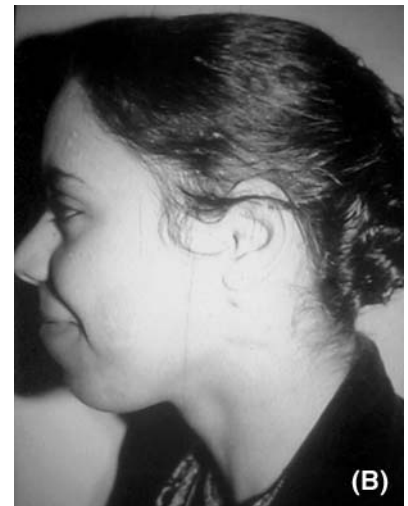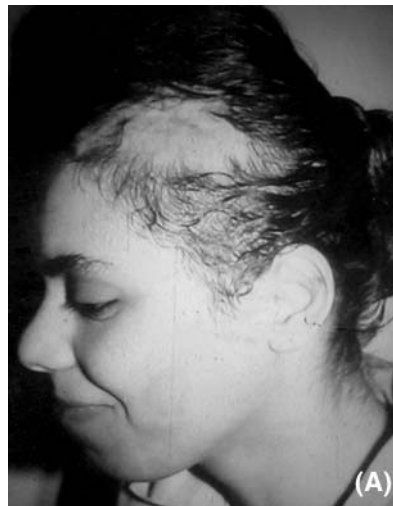sessions with good restoration of the same hair texture and color.

- 2- Incomplete or unsatisfactory coverage: was achieved in five cases (12.5%) in which major complications developed as infection or extrusion.

In this study, the complication rate was 34.75% distributed as 21.5% as minor complications and 13.25% as major complications. Also, the 33.5% of overall complications occurred in pediatric group (less than 15 ys) and 66.5% of the complications occurred in adult group (15-45 ys) (Table 5).

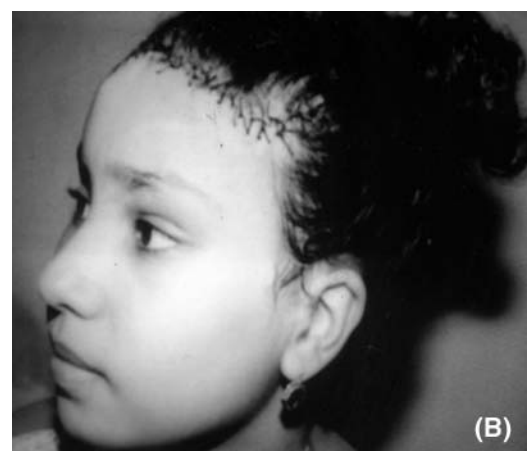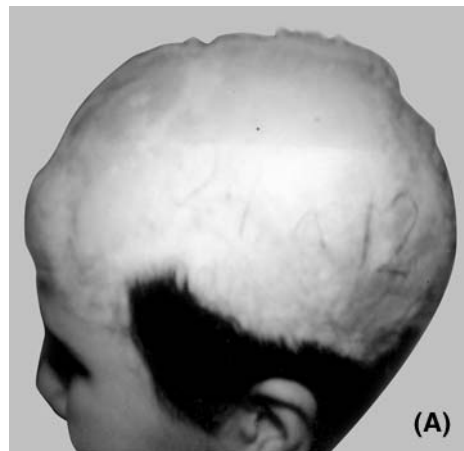
Case (1):

- A- Pre-operative alopecia in temporal region.  
B- Post-operative after reconstruction by rectangular expander 6 months duration.



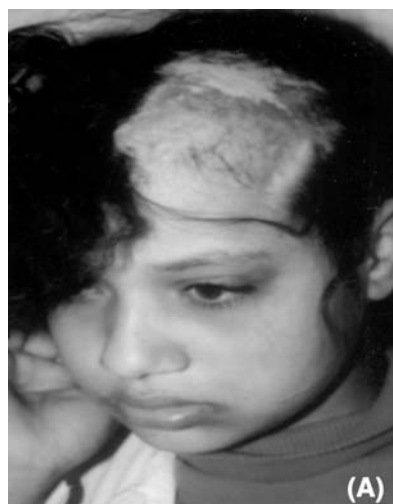Case (2):

- A- Extensive alopecia in child pre-operative.  
B- Post-operative after 3 sessions of expansion.



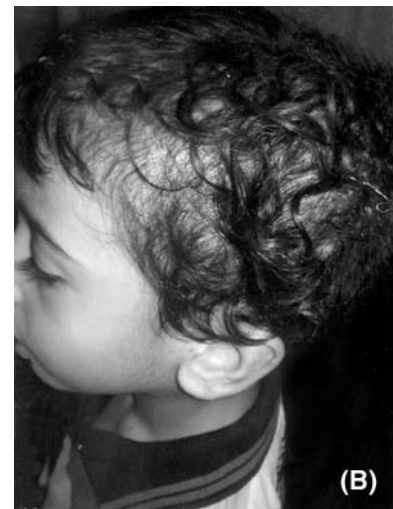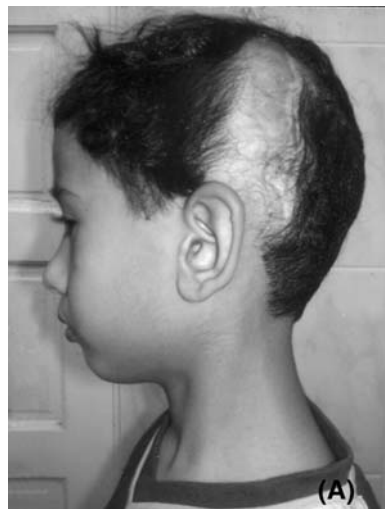Case (3):

- A- Extensive frontal alopecia pre-operative  
B- 1 year follow up after expansion.



## Case (4):

- A- Pre-operative parietal alopecia.  
B- Post-operative view after expansion.



## Case (5):

- A- Alopecia in parietal and occipital area during expansion.  
B- Post-operative after completing expansion process.

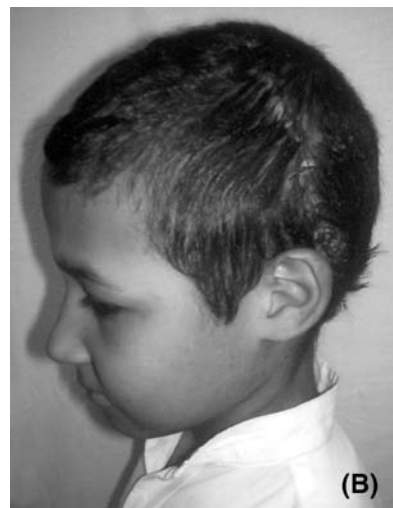
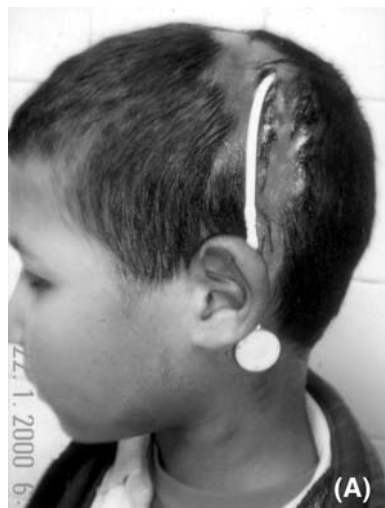
Table (1): Different age distribution among the study.

Age in years	No.
1 ys-14 ys	18
15 ys-45 ys	22
Total	40

Table (2): Different etiology of alopecia.

Etiology of alopecia	No.
Burn	25
Trauma	9
Infection	6
Total	40

Table (3): Different sites of alopecia.

Site of alopecia	No.
Frontal area	15
Parietal and temporal area	22
Occipital area	3
Total	40

Table (4): Different shape of expander used in the study.

Shape of expander	No.
Rectangular	23
Crescent shape	13
Rounded shape	4
Total	40

Table (5): Distribution of complications among different age groups.

Age in years	No. of minor complications	No. of major complications	Percentage of overall complications
1 ys-15 ys (18 patients)	5	1	33.5%
15 ys-45 ys (22 patients)	3	4	66.5%



## DISCUSSION

Since the technique of tissue expansion was popularized by Radovan 1978, cutaneous expansion used increasingly in reconstructive surgery [4]. Now tissue expansion became the most important armamentarium for aesthetic scalp reconstruction as it allows the surgeon to cover large defects using local tissue of appropriate color, texture and adnexal structure with minimal donor site morbidity [1]. The present study analyzed a young population average 19.1 years with predominance of female patients (70%) and the most common indication for tissue expansion was burn (62.5%) this matched with results of Marcelo et al. [5] who worked upon 72 patients with a mean age 20.9 ys, with a predominance of female patients (61.55%) and the most common indication for tissue expansion was burn.

The overall complication in this study was 34.75% which is higher than Gemperli et al. [6] who used tissue expander in 23 patients with overall complications 15.5% but this could be explained as the number of the patients in our study was nearly double the Gemperli work, hence this fact represent more indication for this technique, so many cases of higher complexity were treated resulting in higher complications.

Also our results are lower than Ionomou et al. [4] who worked upon 25 patients recording 44% complication rate.

Also in this study the pediatric group recorded 33.5% out of overall complications, this is lower than Marcelo et al. [5] who recorded 45% complications rate in children and higher than Friedman et al. [7] who recorded 18% complication rate.

The mean time for full expansion was 45 days which was lower than Chune & Rohrich [4] series

who recorded 86 days, this could be explained by our relative lower complication rate than them which allowed us to pass in smooth expansion period.

Also we find no relation between complication rate and type of expander or specific site in the scalp.

From this study we concluded that tissue expansion is useful method of achieving scalp reconstruction where there is little available tissue.

The best results depend on careful patient selection, meticulous attention to details of surgical manouver including good homeostasis, adequate pocketing and fine handling of expander.

## REFERENCES

- 1- Fan J. and Yang P.: Aesthetic reconstruction of burn alopecia by using expanded hair-bearing scalp flaps. *Rev. Stomatol. Chir. Maxillofac.* Aug., 98 (2); 104-8, 1997.
- 2- Bauer B.S., Johnson P.E. and Lovato G.: Application of soft tissue expansion in children. *Clin. Plast. Surg.*, 14: 549, 1987.
- 3- Ionomou T.G., Michelow B.J. and Zuker R.M.: Tissue expansion in pediatric patient. *Ann. Plast. Surg.*, 31: 134, 1993.
- 4- Chun J.T. & Rohrich R.J.: Versatility of tissue expansion in head neck burn reconstruction. *Br. J. Plast. Surg. Apr.*, 51 (3): 186-90, 1998.
- 5- Marcelo S.C., Hugo A.N., Marisa R.H., Jose C.F., Gamperli R. and Marcus C.F.: Tissue expansion complications in plastic surgery. 10 years experience. *Rev. Hosp. Clin.* Vol., 57, No. 3 Sao Paulo May/June 2002.
- 6- Gemperli R., Ferreira M.C. and Manders E.K.: O uso de expansores de tecidos no couro cabeludo. *Rev. Hosp. Clin. Fac. Med. S Paulo*, 46: 112-115, 1991.
- 7- Friedman R.M., Ingram A.E. and Rohrich R.J.: Risk factors for complications in pediatric tissue expansion. *Plast. Reconstr. Surg.*, 98: 1242, 1996.